



Effects of Huanglian Ointment on Wound Healing in Mice with Deep Second-Degree Burns and the Related Mechanism

Houdong Li, Chenghua Xu, Jianghui Tu, Meilin Yi

Three Gorges University Hospital of Traditional Chinese Medicine & Yichang Hospital of Traditional Chinese Medicine, Yichang 443003, Hubei, China

Abstract: Objective: To investigate the effect of Huanglian ointment on wound healing in mice with deep second-degree burns and its potential mechanism. Methods: Sixty BALB/c mice were randomly divided into a Huanglian ointment group and a Vaseline group (control). A deep second-degree burn model was established on the dorsal skin. After modeling, the wounds of the two groups were covered with Huanglian ointment gauze and Vaseline gauze, respectively, with daily dressing changes. Wound healing was observed on days 0, 3, 7, and 17 after injury, and the eschar dissolution rate and healing rate were calculated. Wound tissues were collected at each time point for histopathological examination by H&E staining. ELISA was used to determine the levels of inflammatory factors (TNF- α , IL-1 β , IL-6) and growth factors (VEGF, bFGF) in the wound tissues. Results: Compared with the Vaseline group, the Huanglian ointment group showed faster eschar dissolution and wound healing. On day 7 after injury, the eschar dissolution rate (22.36 \pm 0.95)% was significantly higher than that of the control group (12.69 \pm 0.47)%. On day 17 after injury, the healing rate (93.19 \pm 4.53)% was also significantly higher than that of the control group (74.54 \pm 3.37)%. Histological analysis showed reduced inflammatory cell infiltration and increased, more orderly arranged neovascularization and collagen formation in the Huanglian ointment group at days 7 and 17. ELISA results indicated that the levels of TNF- α , IL-1 β , and IL-6 were significantly decreased, while VEGF and bFGF levels were significantly increased in the Huanglian ointment group on day 7 after injury. Conclusion: Huanglian ointment can effectively promote wound healing in mice with deep second-degree burns, and its mechanism may be related to inhibiting inflammatory responses and upregulating the expression of growth factors.

Keywords: Huanglian ointment; deep second-degree burns; wound healing

1. Materials and Methods

1.1 Experimental Materials

1.1.1 Experimental Animals and Instruments

SPF (Specific Pathogen Free) grade BALB/c male mice weighing 24–26 g were purchased from the Hubei Provincial Laboratory Animal Research Center (Animal Production License No.: SCXK (E) 2022-0018). The animals were housed in the Experimental Animal Center of Three Gorges University under controlled environmental conditions: room temperature (23 \pm 3) $^{\circ}$ C, relative humidity (60 \pm 5)%, and a 12 h light/dark cycle. All mice had free access to food and water, and bedding was regularly changed. After one week of acclimatization, the mice were grouped. All animal experiments were approved by the Animal Ethics Committee of Three Gorges University (2020B010C) and conducted in accordance with the “Guidelines for the Care and Use of Laboratory Animals of Three Gorges University.” The laboratory animal facility license number is SYXK (E) 2022-0061.

TYPE1500-458 full-wavelength microplate reader (Thermo Fisher Scientific, USA); CKX53 inverted fluorescence microscope (Olympus, Japan); EG 1150C ultrathin microtome (Leica, Germany); 5424R refrigerated high-speed centrifuge (Eppendorf, Germany).

1.1.2 Experimental Drugs and Reagents

The Huanglian ointment used in this study was a self-prepared formulation of Yichang Hospital of Traditional Chinese Medicine. It is composed of several traditional Chinese medicinal herbs, including Huanglian (*Coptis chinensis*), Huangbai (*Phellodendron amurense*), Jianghuang (*Curcuma longa*), Shengdi (*Rehmannia glutinosa*), Danggui (*Angelica sinensis*), among others, and has the functions of clearing heat and detoxification and promoting meridian circulation.

TNF- α , IL-1 β , IL-6, VEGF, and bFGF ELISA kits were purchased from Wuhan Boster Biological Engineering Co., Ltd.

1.2 Experimental Methods

1.2.1 Animal Grouping and Model Establishment

Sixty male SPF-grade BALB/c mice (weighing 24–26 g) were selected and randomly divided into a Huanglian ointment group and a Vaseline group, with 30 mice in each group. After one week of adaptive feeding, both groups of mice were anesthetized by intraperitoneal injection of 4% chloral hydrate. The dorsal hair was clipped within an area of approximately 3 cm×3 cm, followed by hair removal using 8% sodium sulfide solution and disinfection with 75% ethanol. Under a laminar flow hood, a thermostatic and constant-pressure burn apparatus was used to create deep second-degree burn wounds by applying a temperature of 94°C to the dorsal skin for 8 seconds, producing a circular wound with a diameter of 1.5 cm. Within 1 hour after injury, the wounds of the Huanglian ointment group and the Vaseline group were covered with Huanglian ointment gauze (prepared by evenly spreading Huanglian ointment onto sterile gauze and sterilizing at high temperature; the ointment content was approximately 0.3 g/cm²) and Vaseline gauze, respectively. A sterile dry gauze dressing was applied externally, followed by fixation with self-adhesive bandage. Dressing changes were performed once daily for a total of 17 days. All mice were housed individually under standard laboratory conditions with free access to food.

1.2.2 Macroscopic Observation of Wound Surface and Calculation of Eschar Dissolution Rate and Wound Healing Rate

(I) During each dressing change, the macroscopic healing conditions of the wounds in both groups of mice were observed, including wound size, color, redness and swelling around the wound, granulation tissue growth, and epithelialization.

(II) Wound healing rate: On days 7 and 17 after injury, the wound healing conditions of the two groups were observed. The wound area was measured by photography combined with transparent grid paper, and the wound healing rate was calculated using ImageJ image analysis software.

Wound healing rate = (Original wound area – Unhealed wound area) / Original wound area × 100%.

(III) Eschar dissolution rate: On day 7 after injury, the eschar dissolution of the wounds in the two groups was observed. By photographing and using transparent grid paper to trace the edge of the wound eschar, the eschar dissolution rate was calculated using ImageJ.

Eschar dissolution rate = (Initial eschar area – Eschar area at the time point) / Initial eschar area × 100%.

1.2.3 Hematoxylin–Eosin (H&E) Staining for Observing Morphological Changes in Mouse Wound Skin Tissue

After collection, the tissue samples were placed in embedding cassettes and immediately fixed in 4% paraformaldehyde for 24 h to ensure adequate fixation. The samples were then subjected to graded ethanol dehydration and xylene clearing. After dehydration, the tissues were immersed in paraffin using a paraffin embedding machine for paraffin embedding. Routine hematoxylin–eosin (H&E) staining was performed, and the wound tissue structure, inflammatory cell infiltration, and neovascularization were observed under a microscope.

1.2.4 ELISA Detection

Frozen wound skin tissues were lysed and centrifuged at 12,000 r·min⁻¹ for 5 min at 4°C. The supernatant was collected, and TNF- α , IL-1 β , IL-6, VEGF, and bFGF levels in the supernatant were quantitatively detected according to the instructions of the ELISA kits, to evaluate the expression levels of inflammatory factors and growth factors in the wound tissues of each group.

1.3 Statistical Analysis

Data were analyzed using GraphPad Prism 9.0 software and expressed as ($\bar{x} \pm s$). An independent t-test was used, with $P < 0.05$ indicating statistically significant differences and $P < 0.01$ indicating highly significant differences.

2. Results

2.1 Macroscopic Observation of Wound Surface and Eschar Dissolution Rate and Healing Rate

On day 0 after injury, the wounds were swollen with a red-white interlaced base. On day 3 after injury, the wounds in both groups were dry and scabbed. Eschar dissolution began in the Huanglian ointment group, while no obvious eschar dissolution was observed in the Vaseline group. On day 7 after injury, the wound areas in both groups had decreased. In the Huanglian ointment group, the wound edges showed no obvious redness or swelling, the eschar dissolution area increased significantly, and granulation tissue growth was visible. In the Vaseline group, the wound edges remained red and swollen, the scab became thinner, and only a small amount of eschar dissolution was observed. On day 17 after injury, most wounds in the Huanglian ointment group had healed, while the remaining unhealed area in the Vaseline group was still clearly visible. See Figure 1. After 7 days of treatment, there was no statistically significant difference in wound healing rate between the two groups. After 14 days of treatment, the wound healing rate in the Huanglian ointment group was significantly higher than that in the Vaseline group. After 7 days of treatment, the eschar dissolution rate of the Huanglian ointment group was

significantly higher than that of the Vaseline group. See Table 1.

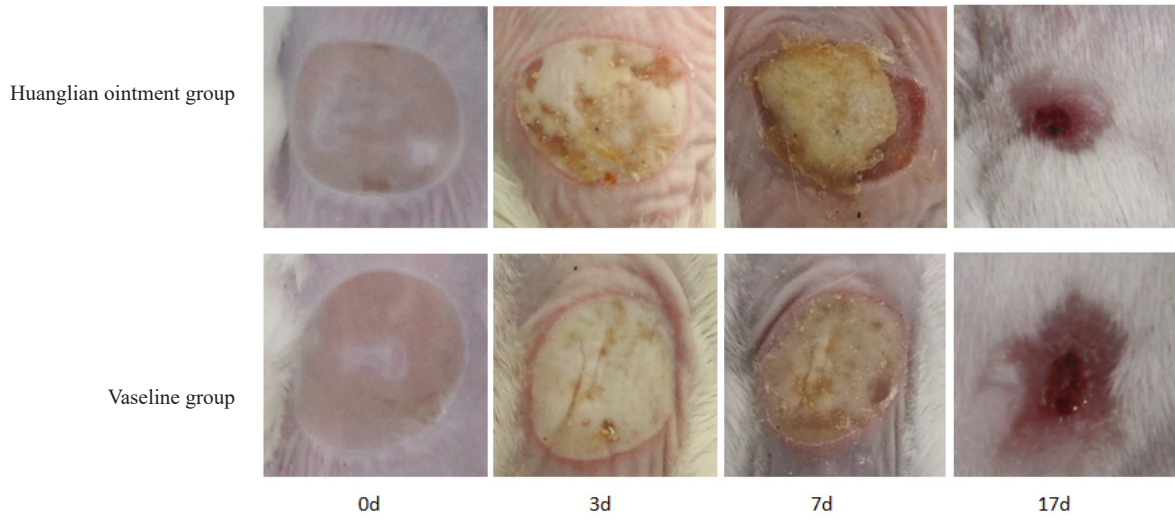


Figure 1. Wound healing status of mice in the two groups

Table 1. Effects of Huanglian Ointment on Eschar Dissolution Rate and Wound Healing Rate in Mice with Deep Second-Degree Burns (% , $\bar{x}\pm s$, n=10)

Group	Eschar Dissolution Rate on Day 7	Wound Healing Rate	
		Day 7	Day 17
Huanglian Ointment Group	22.36±0.95*	23.37±2.45 Δ	93.19±4.53*
Vaseline Group	12.69±0.47	17.62±1.80	74.54±3.37

Note: Compared with the Vaseline group, *P< 0.05, Δ P>0.05

2.2 Effect of Huanglian Ointment on Wound Healing of Deep Second-Degree Burns in Mice Observed by H&E Staining

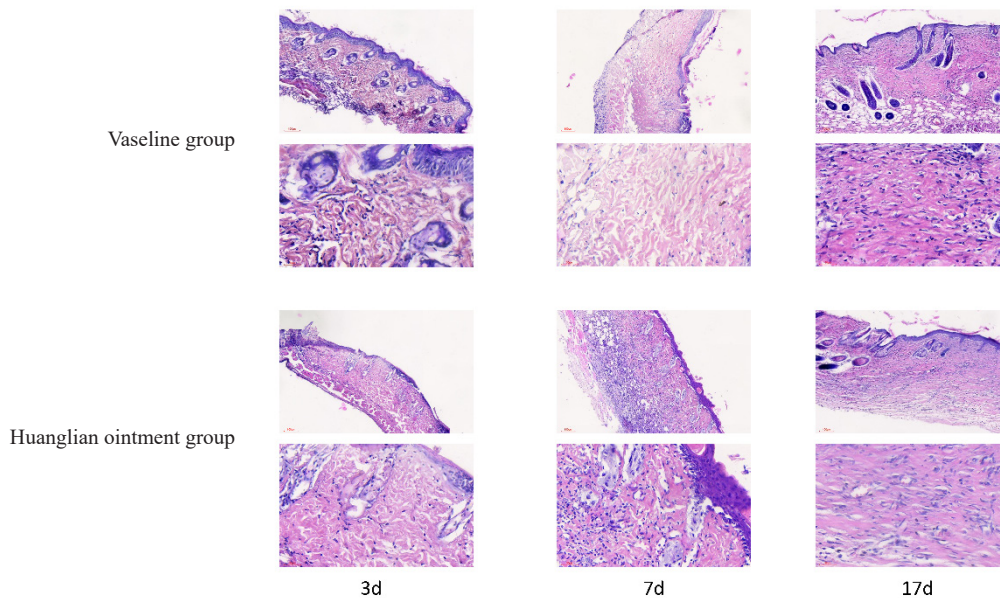


Figure 2. Comparison of H&E staining of the Vaseline group and Huanglian ointment group on days 3, 7, and 17 (upper: 5 \times , lower: 10 \times)

Compared with the Vaseline group, both groups showed a large number of inflammatory cells and few newly formed blood vessels on day 3 after injury. On day 7 after injury, the Huanglian ointment group exhibited a marked reduction in inflammatory cells, with numerous newly formed blood vessels and collagen fibers. On day 17 after injury, the Huanglian

ointment group showed more neovascularization and collagen deposition, fewer inflammatory cells, and neatly arranged collagen fibers.

2.3 Comparison of Inflammatory Factor Levels in Wound Tissues

On day 7 after injury, compared with the Vaseline group, the levels of TNF- α , IL-1 β , and IL-6 in the wound tissues of mice in the Huanglian ointment group were significantly decreased, with statistically significant differences ($P < 0.01$) (Table 2).

Table 2. Effects of Huanglian Ointment on Inflammatory Factor Levels in Burn Wound Tissues ($\bar{x}\pm s$, n=10)

Group	TNF- α (pg·mL ⁻¹)	IL-1 β (pg·mL ⁻¹)	IL-6 (pg·mL ⁻¹)
Huanglian Ointment Group	75.94 \pm 7.23*	297.04 \pm 16.35*	243.72 \pm 15.35*
Vaseline Group	131.05 \pm 11.34	560.82 \pm 21.28	663.55 \pm 25.53

Note: Compared with the Vaseline group, * $P < 0.01$.

2.4 Comparison of Growth Factor Levels in Wound Tissues

On day 7 after injury, compared with the Vaseline group, the levels of VEGF and bFGF in the wound tissues of mice in the Huanglian ointment group were increased, with statistically significant differences ($P < 0.05$) (Table 3).

Table 3. Effects of Huanglian Ointment on Growth Factor Levels in Burn Wound Tissues ($\bar{x}\pm s$, n=10)

Group	VEGF (pg·mL ⁻¹)	bFGF (pg·mL ⁻¹)
Huanglian Ointment Group	144.36 \pm 7.52*	24.17 \pm 2.07*
Vaseline Group	106.03 \pm 4.33	15.84 \pm 1.79

Note: Compared with the Vaseline group, * $P < 0.05$.

3. Discussion

Traditional Chinese medicine considers “fire-heat pathogenic factors” as the cause of burns. Early external invasion of fire-heat can lead to obstruction of wound meridians and stagnation of qi and blood, which, if prolonged, may generate toxic pathogenic factors. Therefore, most commonly used topical Chinese medicines clinically have the effects of clearing heat and detoxifying, promoting blood circulation and removing blood stasis, and resolving necrotic tissue while promoting tissue regeneration. Huanglian ointment is widely used for second-degree burn wounds, post-skin graft wounds, donor site wounds, and chronic non-healing wounds, achieving good clinical results. Its formulation includes Huanglian (*Coptis chinensis*), Huangbai (*Phellodendron amurense*), Jianghuang (*Curcuma longa*), Shengdi (*Rehmannia glutinosa*), and Danggui (*Angelica sinensis*). In this formulation, Huanglian and Huangbai clear heat, dry dampness, and detoxify; Jianghuang promotes blood circulation and qi movement; Shengdi cools the blood, nourishes yin, and moistens dryness; Danggui promotes and nourishes blood. The combined use of these herbs exerts the effects of clearing heat and detoxification and unblocking meridians, thereby promoting wound healing [13].

In this study, on day 0 after injury, the wounds in both groups were swollen with a red-white interlaced base. On day 3, the wounds in both groups were dry and scabbed. Scattered eschar dissolution was observed in the Huanglian ointment group, while no obvious eschar dissolution was observed in the Vaseline group. On day 7, the wound areas in both groups were slightly reduced, the wounds were moist, and the scabs softened. In the Huanglian ointment group, the eschar dissolution area increased significantly and granulation tissue growth was visible, whereas in the Vaseline group, the scab began to thin with only a small amount of eschar dissolution. On day 7, there was no significant difference in wound healing between the two groups. On day 17, most wounds in the Huanglian ointment group had healed, while the remaining unhealed areas in the Vaseline group were still obvious. These results indicate that Huanglian ointment can accelerate eschar dissolution and promote wound healing in deep second-degree burn wounds.

During the exudative phase of burns, TNF- α , IL-1 β , and IL-6 are important inflammatory factors that can clear necrotic tissue and pathogens from the wound, promote cell proliferation, angiogenesis, and extracellular matrix formation, thereby creating favorable conditions for wound healing. However, persistent excessive inflammatory responses can hinder fibroblast proliferation and angiogenesis, and lead to microcirculatory disorders, thereby affecting wound healing [14–16]. In this study, after 7 days of intervention with Huanglian ointment, the levels of TNF- α , IL-1 β , and IL-6 in the wound tissues of mice were significantly decreased, and the wound healing rate was significantly increased, suggesting that Huanglian ointment may promote burn wound healing by inhibiting the inflammatory response during the infection phase.

Previous studies have shown that growth factors play a key role in wound healing. VEGF can promote proliferation and migration of vascular endothelial cells to form new blood vessels [17], and bFGF can promote fibroblast proliferation and migration as well as angiogenesis, thereby facilitating wound healing [18–19]. This study found that on days 7 and 17 after injury, compared with the Vaseline group, the levels of VEGF and bFGF in the wound tissues of mice in the Huanglian ointment group were increased. These results suggest that Huanglian ointment can upregulate the expression of growth factors such as VEGF and bFGF, promote angiogenesis and granulation tissue growth, and thereby enhance wound healing.

Acknowledgments

This study was supported by the following funding sources: Yichang Medical and Health Research Project (A23-1-065) and the National Famous Veteran Traditional Chinese Medicine Experts Inheritance Studio Construction Project (National Traditional Chinese Medicine Education Letter [2022] No. 75).

Conflict of Interests

The authors declare no conflict of interests.

References

- [1] Chen Jiankun, Chen Chao. Mechanism of wound healing in second-degree burns [J]. *Guangdong Medicine*, 2009, 11: 1752-1754.
- [2] Akhoondinasab R M, Khodarahmi A, Akhoondinasab M, et al. Assessing effect of three herbal medicines in second and third degree burns in rats and comparison with silver sulfadiazine ointment [J]. *Burns*, 2015, 41(1): 125-131. DOI:10.1016/j.burns.2014.04.001.
- [3] Reza M A, Motahhare A, Mohsen S. Comparison of healing effect of aloe vera extract and silver sulfadiazine in burn injuries in experimental rat model [J]. *World Journal of Plastic Surgery*, 2014, 3(1): 29-34.
- [4] Zhang Xiaofen, Sun Guifang, Chen Yafeng, Ma Jiaoyang, Gao Chunfang, Sheng Xia, Feng Dianxu. Effects and related mechanisms of Huanglian ointment on full-thickness skin defect wound healing in mice [J]. *Chinese Journal of Burns*, 2016, 12: 714-720.
- [5] Shen Jiangyong, Ma Qiang, Yang Zhibin, Gong Jingjing, Wu Yinsheng. Effects and mechanisms of Zicao oil on full-thickness skin defect wound healing in rats [J]. *Chinese Journal of Burns*, 2017, 09: 562-567.
- [6] Xiao Changshuan, Liu Yaping, Sun Kui, Yang Jingzhe, Chen Hongyu. Intervention effect and mechanism of compound Huangbai liquid preparation on deep second-degree burn wounds [J]. *Chinese Journal of Experimental Traditional Medical Formulae*, 2021, 16: 102-110.
- [7] Ding Xiaotong, Wang Yiwei, Min Wen, Chen Jun. Therapeutic effect of *Macrolepiota* spore ethanol extract on full-thickness skin defect wounds in mice [J]. *Chinese Journal of Experimental Traditional Medical Formulae*, 2022, 08: 149-158.
- [8] Zhao Qiansi, Wang Xiong, Wu Jinhu. Research progress on the mechanisms of topical Chinese medicine promoting burn wound healing [J]. *Medical Review*, 2014, 16: 3003-3005.
- [9] Ding Ling, Chen Zhiwei. Research progress on the mechanisms of topical Chinese medicine promoting wound healing [J]. *Jiangsu Traditional Chinese Medicine*, 2006, 12: 71-72.
- [10] Xie Longwei, Gu Zaiqiu, Cai Liangliang. Clinical observation of Huanglian ointment in the treatment of early burns in 41 cases [J]. *Henan Traditional Chinese Medicine*, 2014, 12: 2487-2488.
- [11] Meng Yazhi, Zhang Jing, Li Jun. Clinical observation of compound Huanglian ointment in the treatment of diaper dermatitis in children [J]. *Modern Journal of Integrated Chinese and Western Medicine*, 1999, 03: 465.
- [12] Duan Yanfang. Treatment of second-degree burns in 200 cases using Huanglian gauze strips [J]. *Hubei Journal of Traditional Chinese Medicine*, 1996, 02: 41.
- [13] Ji Guangqiong, Deng Yanqing, Tan Faming, Chen Zhiguo. Research progress of Huanglian ointment [J]. *Hubei Journal of Traditional Chinese Medicine*, 2018, 03: 55-57.
- [14] Kunimura K, Miki S, Takashima M, et al. S-1-propenylcysteine improves TNF- α -induced vascular endothelial barrier dysfunction by suppressing the GEF-H1/RhoA/Rac pathway [J]. *Cell Commun Signal*, 2021, 19(1): 1-14.
- [15] Alhilali M J, Parham A, Attaranzadeh A, et al. Prognostic role of follicular fluid tumor necrosis factor alpha in the risk of early ovarian hyperstimulation syndrome [J]. *BMC Pregnancy Childbirth*, 2020, 4(20): 1-7.
- [16] Abali A E, Karakayali H, Ozdemir B H, et al. Destructive pulmonary effects of smoke inhalation and simultaneous alterations in circulating IL-6, TNF- α , and IFN- γ levels at different burn depths: an experimental study on rats [J]. *J Burn Care Res*, 2013, 34(3): 334-341.
- [17] Losi P, Briganti E, Errico C, et al. Fibrin-based scaffold incorporating VEGF- and bFGF-loaded nanoparticles stimulates

- wound healing in diabetic mice [J]. *Acta Biomaterialia*, 2013, 9(8): 7814-7821. DOI:10.1016/j.actbio.2013.04.019.
- [18] Gerwins P, Skölden E, Claesson-Welsh L. Function of fibroblast growth factors and vascular endothelial growth factors and their receptors in angiogenesis [J]. *Critical Reviews in Oncology and Hematology*, 2000, 34(3): 185-194. DOI:10.1016/S1040-8428(00)00062-7.
- [19] Yin Lianghong, Gao Ling, Lu Jidong, et al. Research progress on the role of basic fibroblast growth factor in skin injury repair [J]. *Chinese Journal of Biological Products*, 2020, 33(05): 574-580. DOI:10.13200/j.cnki.cjb.002628.