

Transcarotid TAVI: Step by Step Technique

Federico Altamirano-Medel*, Miguel A. Gomez-Vidal, Tomás Daroca-Martinez

Cardiovascular Surgery Department, Puerta del Mar University Hospital, Cádiz, Spain.

Corresponding author. Email address: federicoaltamiranomedel@gmail.com

Abstract: Introduction and objectives: Transcatheter aortic valve implantation as a treatment for aortic stenosis is positioned as the therapy of choice for a specific population of patients, which is steadily increasing and is no longer limited to patients with prohibitively high surgical risk. This stems from the advancement and refinement of devices, as well as the development of different access routes. Our goal is to share and standardize the transcarotid access technique, which we have implemented and developed since 2019 with very good results. Method and results: Between 01/01/2019 and 31/12/2023, 79 transcatheter valves were implanted via the carotid route (21.43% of the total implants in our center), with no intraoperative mortality and less than 1% mortality during the first month of intervention. The incidence of established strokes in these patients is 0%. Conclusions: We have adopted the transcarotid route as an equally valid alternative to the transaxillary access. Due to recent changes in patient selection criteria, we believe that the cardiovascular surgeon should have an active role in decision-making and implantation of this type of prosthesis, since many patients have low surgical risk and are consequently susceptible to intervention in case of procedure complications.

Key words: transcatheter; aortic stenosis; TAVI; transcarotid; valve

1. Introduction

The first transcatheter valve implantation performed in Rouen (France) in 2002 by Professor Alain Cribier [1] was undoubtedly a milestone in the treatment of severe symptomatic aortic stenosis and the beginning of an arduous debate on the most appropriate access route for the patient. Devices have been evolving and improving. Thus, the transarterial route has become the primary access due to its ease of use, compared to the transapical or transthoracic, with the right transfemoral access being the most common. There are various pathologies that prevent access via the femoral route, such as patients with peripheral arteriopathy of the iliofemoral axis or of the abdominal or thoracic aorta, which currently represent around 10-15% of all patients who are candidates for transcatheter aortic valve implantation (TAVI) [2].

All access routes other than the transfemoral approach have been classified in the clinical guidelines as "non-femoral TAVI", although transarterial (axillary and carotid) are substantially different from transthoracic (apical and transaortic), which undoubtedly represent a greater aggression and, consequently, worse results. Thus, when a patient is found to have a suboptimal iliofemoral axis, a new range of possibilities opens up regarding access routes, the final choice of which will depend on the results and experience of each center and each surgeon.

Initially, open transfemoral and transapical access via left mini-thoracotomy was used, since the devices were quite thick [3]. After the improvement of the caliber of the devices, percutaneous femoral, aortic, axillary and carotid access gradually appeared. There are no double-blind comparative studies between the different peripheral transarterial access

routes such as axillary or carotid. The studies that have been done comparing both accesses are when the transfemoral route is not feasible, and despite being worse patients, the results are similar, and even in some parameters even better [4, 5].

Thus we arrived at the first transcatheter valve implantation via the carotid artery, performed in 2009 [6]. This implant obtained good initial results, despite the initial "fear" of the complications that could arise from manipulation of this artery, especially with regard to neurological complications. However, we cannot forget that patients implanted via the transfemoral route can also suffer these neurological complications, as shown in the main series. Thus, for example, according to the French Registry [5], incidences of stroke or transient ischemic attack have been seen in around 1.6% of patients undergoing implantation via the carotid artery, these figures being even higher in those patients in whom the main access route was the transfemoral route, according to the PARTNER 2 or PARTNER 3 study [7].

At Puerta del Mar University Hospital, we have been using TAVI technology since 2010 and have completed all approaches from the apical, transaortic, and open femur to percutaneous femur, axilla [8] since 2019. Finally, the cervical approach has achieved very good results, which is very similar to the axillary approach and even better in some parameters. We will comment below. The aim of this article is to share our experience and explain the standardized technique for its performance, so that it can be implemented in other centers, often even as an alternative to the femoral approach.

2. Methods

2.1 Preoperative workup

Once the patient has been diagnosed with severe aortic stenosis, the preoperative study is completed with a complete blood analysis, coronary catheterization and a thoracoabdominal angioCT including supra-aortic trunks. To this end, it is important to inform the radiology department of each center of the main particular characteristics required of the angioCT scan for the TAVI study (Table 1).

Table 1. Characteristics of an IV contrast-enhanced angioCT for preoperative TAVI study

- Must include from supra-aortic trunks to femoral arteries.
- Cuts at least 0.3 mm in diameter.
- Synchronized with the R-R, at least 40%.
- Preferably contrast should be administered through the right arm, as the last preferred access routes for TAVI are the right subclavian and right carotid arteries.

Source: own elaboration.

Subsequently, the patient must be presented to the medical-surgical committee (Heart Team), composed of interventional cardiologists, cardiovascular surgeons, intensivists and anesthesiologists, where the indication for TAVI and the most suitable access route will be decided.

In all patients, measurements for planning must be performed with specific software; in our case we use the so-called 3mensio™ (fig. 1), where it is mainly evaluated:

- Caliber, tortuosity and parietal calcifications of femoral, axillary, subclavian and bilateral carotid arteries.
- Measurements of the aortic annulus; left ventricular outflow tract (LVOT), sinuses and sinotubular junction (STJ).
- Height of the coronary arteries.
- Radiological projections where the leaflets will be seen aligned (commonly referred to as "working projections") and which should be used during the procedure.

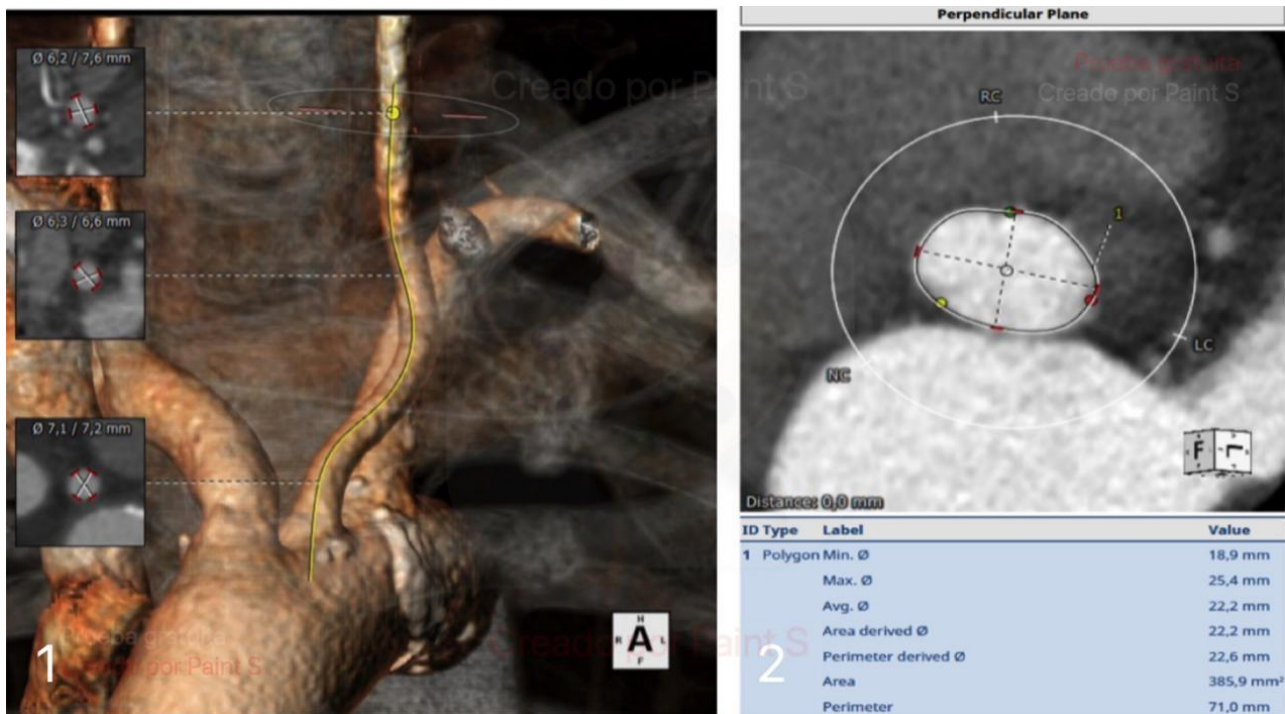


Figure 1. A) Reconstruction of left carotid artery and B) standardized measurement of aortic annulus. Both performed using 3mensio™ software. Source: own elaboration.

Carotid access will be considered when the femoral access is suboptimal or we find inconveniences in the route, either abdominal or thoracic aorta, and the carotid artery has an adequate diameter in its course and anatomical characteristics equal to or better than the left axillary artery. In our center, we do not use a protocolized preoperative study of cerebral circulation, but we perform an intraoperative test of adaptation to ischemia, as we will discuss later.

2.2 Surgical procedure

2.2.1 Characteristics of the intervention

Once the study is completed and the surgical procedure is selected through the carotid artery access, the intervention in our center has the following characteristics:

- (1) The procedure is performed in the operating room under general anesthesia.
- (2) The extracorporeal circulation pump (ECP) is always available and ready to come into operation in the event of an emergency arising from a complication and a change to conventional surgery is required. This point is of particular importance, especially as the indicated age of the patients is getting younger and younger and, therefore, these patients are operable.
- (3) The intervention is also performed under transesophageal echocardiographic control, to evaluate the level of height of the prosthesis, or the presence of periprosthetic leaks more reliably. This control offers the possibility of assessing possible inconveniences or complications during the procedure.
- (4) Unlike other vascular accesses for TAVI, it is essential to have cerebral oximetry (INVOS™) that allows continuous intraoperative monitoring, while we are going to clamp one of the carotid arteries.

2.3 Organization of the operating room

As it happens in every transcatheter procedure, X-ray equipment must be available. In our case, we use a mobile arc type equipment (Siemens™ Cyos Alpha) with specific software for TAVI. The sterile surgical table should be of a long rectangular type (Fig. 2), perpendicular to the patient's head, for better handling of instruments, guides and catheters.

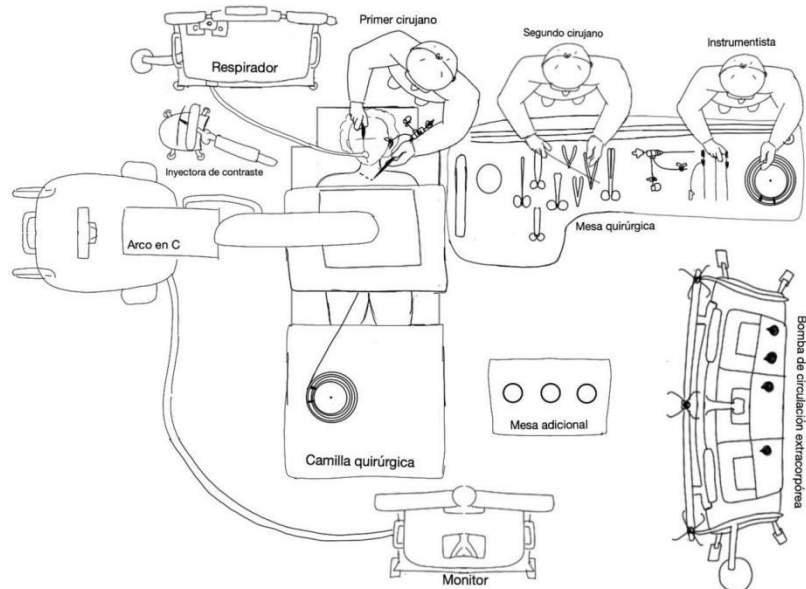


Figure 2. Diagram of the organization of the operating room during the prosthesis implantation phase. Source: own elaboration.

2.4 Surgical technique

The surgical procedure should be performed by both surgeons simultaneously.

First surgeon. He faces the patient's head and performs the following actions:

- (1) Incision (fig. 3) between one and three cm above the left clavicle, approximately 5 cm long, over the anterior border of the sternocleidomastoid (SCM).

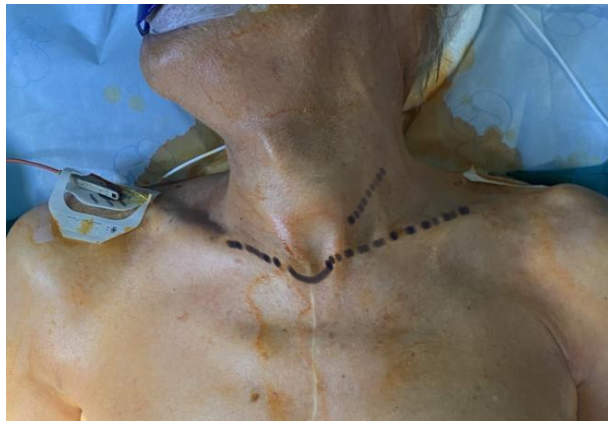

Figure 3. Planning of the incision before starting the procedure. Source: own elaboration.

- (2) Dissection by planes, in the following order: a) subcutaneous cellular tissue; b) platysma muscle, and c) blunt dissection of the MCE, with the aid of Adson's retractor, so that the MCE is tractioned laterally and the vasculonervous bundle is opened. The common carotid artery (CCA) is dissected by delicately separating it from the internal jugular vein, towards the external face of the same (in some cases, ligation of the facial vein or facial thyroid trunk is useful, if it crosses the midline).

- (3) CCA control (fig. 4) using two vessel loops. We expose the vessel and make a tobacco pouch in the longitudinal axis of the artery, using a 4-0 monofilament, with an approximate length of 10 mm and a separation of 2 mm, just the right diameter to be able to place the 18G needle and the guide for the initial introducer (5F). In the use of this bag, we have not registered any complications of stenosis type at the end of the procedure.

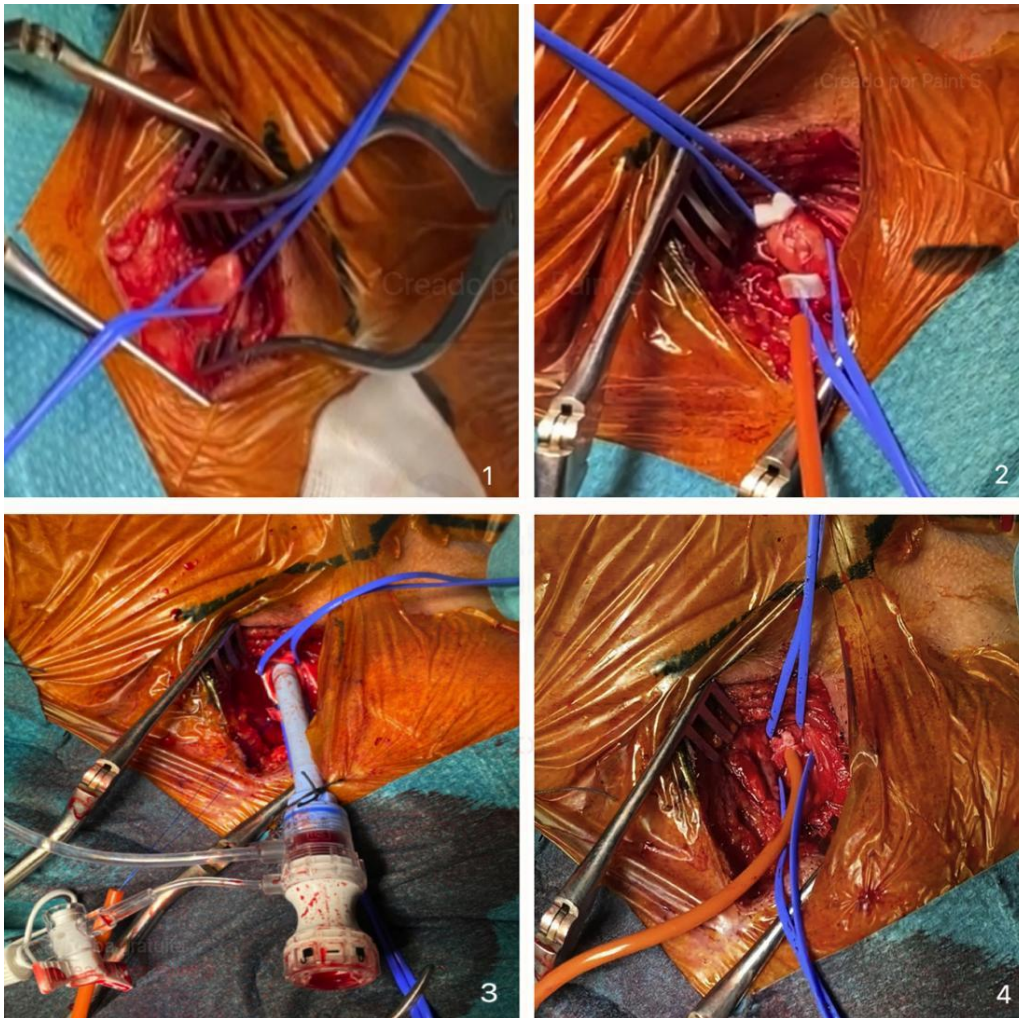


Figure 4. 1) Exposed primitive carotid artery; 2) tobacco pouch placement; 3) controlled opening and introducer; and 4) tobacco pouch closure. Source: Own elaboration

(4) Cerebral collateral circulation test. The exposed carotid artery is clamped for five minutes, being evaluated by means of cerebral/somatic oximetry (INVOS™ Somanetics from Medtronic) for the compensation of the ipsilateral hemisphere, thanks to the cerebral collateral circulation and the polygon of Willis. We particularly emphasize this part of the technology because there is no preoperative study using cerebral circulation in our center.

Only in one case in our series did the oximetry of the homolateral side drop more than 20% of the initial value, and we considered using a shunt. We finally decided not to use it, and continued the implant without any consequence for the patient. Therefore, at present, we have not used carotid shunt in any case for these procedures, which are relatively fast, even faster than transfemoral implants, since catheter navigation is minimized and they are at a short distance from the aortic valve.

Second surgeon. It is initially located at the level of the patient's pelvis or contralateral arm, depending on the vascular accesses used to raise the reference pigtail, and performs the following actions:

(1) Puncture of the common femoral or left radial artery using the Seldinger technique, under echocardiographic control. It is also plausible to perform the puncture in the humeral artery, for placement of the 6F introducer.

(2) Raise the curved Teflon guidewire to the aortic valve and place a pigtail catheter outside the coronary sinus for anatomical reference and contrast injection. At this point, we can perform reference aortography to evaluate the position of the pigtail, the height of the coronary arteries and the visible degree of valvular regurgitation, if it is a double lesion.

(3) Contralateral femoral vein puncture as a protective measure in case of complications and emergency CPB entry. During the procedure, a long Teflon guidewire is left in place to cannulate the ilio caval-femoral axis.

(4) Ipsilateral venous puncture, placement of a central line (useful for anesthesiology) and placement of a transient pacemaker under radioscopic control, for rapid stimulation during the procedure, which the patient will maintain during the first 24-48 hours postoperatively. If permanent high-grade AV block is present, the transient pacemaker is removed after placement of a permanent pacemaker. This step can be performed by anesthesiology, through the right subclavian artery, prior to the start of the procedure, at the choice of the surgical team.

2.5 Prosthesis implantation procedure

The procedure for implanting the prosthesis is detailed below.

(1) Using Seldinger's technique, we place a 5F introducer inside the tobacco pouch. Subsequently, we introduced a curved Teflon guidewire up to the aortic valve and advanced a Boston Amplatz Left (AL1) catheter to bring it closer and orient it towards the valvular orifice.

(2) After exchanging for a straight guidewire, either Teflon-coated or hydrophilic, we cross the stenotic aortic valve, trying to synchronize the movement of the guidewire with cardiac systole, so as to achieve crossing in one heartbeat. For this, we usually use the AL1 catheter; we can exchange it for an AL2 catheter or a Judkins right 4 (JR), useful in more verticalized aortic valves when changing the angulation (8).

(3) Once traversed, we advance the catheter into the ventricle. At this point, it is important to emphasize the importance of blood reflux through the catheter, to ensure that it is in the ventricular cavity and that it is not making a wall with the endocardium. Special care should be taken in this maneuver, as it can cause a high rate of arrhythmias due to endocardial manipulation.

(4) We replace the straight Teflon guidewire with a preformed high-support guidewire. In our case, we used Boston Safari™. When introduced through the catheter, we obtain its characteristic snail shape (fig. 5).

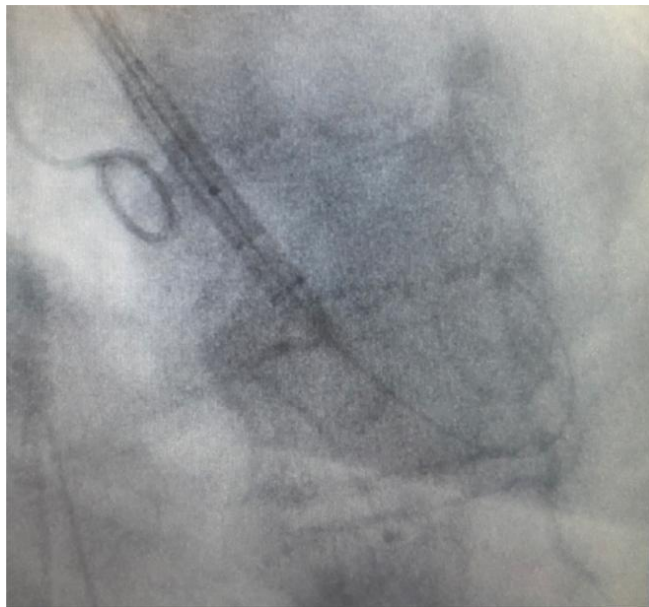

Figure 5. Safari guidewire in the left ventricle and balloon expandable valve advancing toward the aortic annulus. Source: own elaboration.

(5) Change the introducer. We remove the 5F introducer, leaving the rigid guide, through which we place a Gore introducer (Dry Seal™). The size will depend on the size of the prosthesis (18F or 20F), in the cases of Navitor 23-25 and Navitor 27, 29 prostheses, respectively.

In our center, as the carotid access is shorter and closer to the aortic valve, we cut the introducer with a scalpel to achieve a length of 13-15 cm and, therefore, greater comfort at the time of manipulation (Fig. 6). The introducer should be placed in a longitudinal axis to the artery, using a No. 11 scalpel to achieve a controlled opening of the vessel, a key point for subsequent hemostasis.

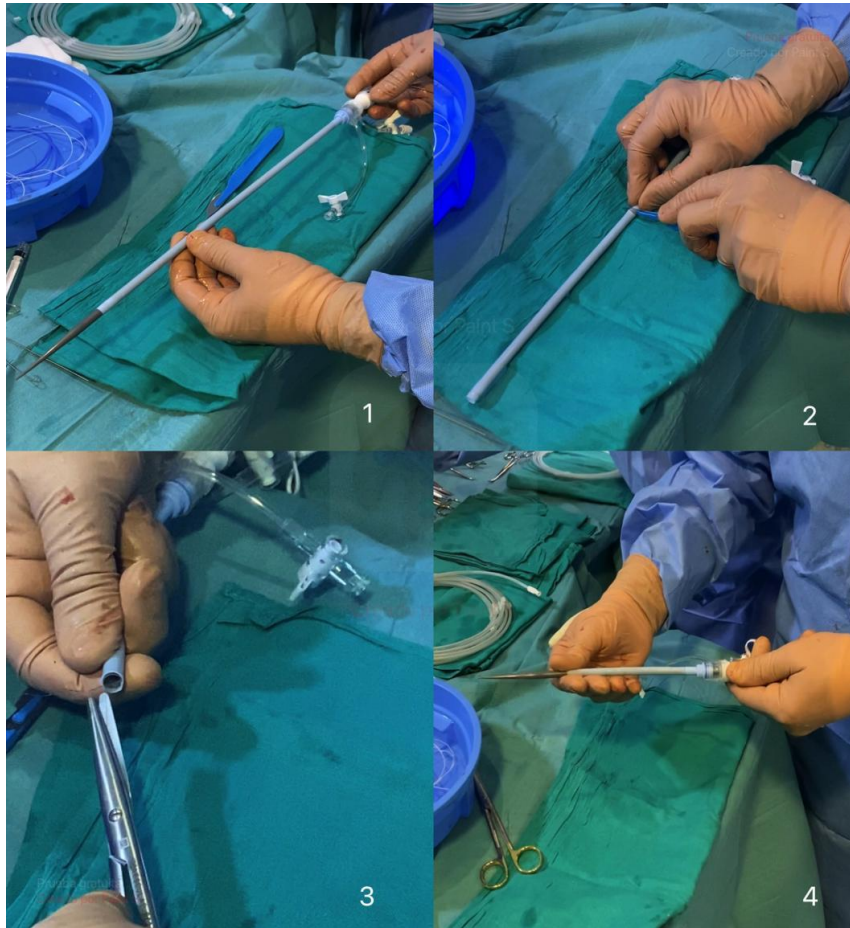


Figure 6. Section of the introducer with scalpel and placement of the dilator. Source: Own elaboration.

(6) Prior balloon dilatation, if required in the case (useful in very calcified valves). In our center, we use a compliant OPSIKA VACS II™ valvuloplasty catheter, for which we use as balloon size the minimum diameter measured by 3D reconstruction in the case study. We performed the valvuloplasty during rapid pacing with the transient pacemaker at 160-180 bpm.

(7) Introduction of the device delivery. Progression is made in the direction of the aortic valve, using the pigtail as a reference, which should always be positioned at the nadir of the non-coronary sinus, until the inferior reference point of the valve is approximately 1-2 mm below the pigtail. During deployment, the prosthesis tends to dive towards the ventricle and finally remain at 3-5 mm, which is our objective.

(8) In our center, we use moderate stimulation (120-140) in self-expandable prostheses, to have a systolic blood pressure around 80, since, although it is not strictly necessary, in our experience, it helps to better control the deployment of the prosthesis. This type of prosthesis has two deployment phases. The first phase is progressive and slow, and is partial until 70% is reached. At this point, the prosthesis is functional (i.e., it produces hemodynamic stability in the patient, allows the surgeon to keep calm and, in case the position is not the desired one, or an inadequate height is evidenced, it allows us to fold again and reposition it).

If we are satisfied with the position, we continue with the second phase of the deployment. This would be the point of "no return". The objective of this deployment is to place the prosthesis between 3 and 5 mm below the native aortic annulus.

In the case of balloon-expandable prosthesis, the implantation system is different, and it is mandatory to use rapid stimulation in cases in which we use a balloon-expandable valve (Sapien Edwards™, MyValve Meril™). In addition, contrast injection is performed during deployment. These prostheses have a disadvantage: they have no possibility of re-positioning once implanted, and the target height is different. They should be positioned with 40% in the left ventricle (LV) and 60% in the aorta, or with a 30/70 split, although the current trend in our recent cases is to position them higher, with a 20/80 split.

(9) We then check the result. By means of transesophageal echocardiography and direct arteriography, we evaluate the position of the prosthesis and whether or not periprosthetic leaks are present.

If we use a Navitor™ and Evolut prosthesis, for mild leaks, in our experience, it is convenient to wait about 5 to 10 minutes and reevaluate, since they have an external sheath that molds to the left ventricular outflow tract (LVOT) for periprosthetic leak reduction. In case of medium-severe leaks, we can opt for post balloon dilatation, for which we do not remove the support guidewire, thus avoiding having to reinsert a Teflon-coated guidewire or pigtail through the recently implanted prosthesis. In this case, the procedure explained in step 6 would be repeated.

(10) Removal of the guidewire and catheter release system. As in any other endovascular procedure, we remove the prosthesis release system, taking into account that the nose of the system does not collide with the implanted prosthesis, since it could get caught and inadvertently mobilize.

We must also pick up the system, although in the cases that we use Dryseal™ introducer we can skip this step, because all the access is protected by the introducer. Finally, we remove the introducer, close the tobacco pouch, and evaluate the patency of the artery by palpation, and if necessary or if we have any doubts, perform angiography with the pigtail or selectively cannulate the carotid artery. We perform hemostasis control and closure by planes with intradermal suture for better aesthetic result. If the route to raise the pigtail was femoral, percutaneous closure of this vessel with Angioseal™ is usually performed.

Ethical considerations

All patients who took part in the present study signed an informed consent form beforehand, which included, among other issues, the use of images for teaching purposes or for the dissemination of scientific knowledge.

3. Results

Our service started its own TAVI program in 2011. Up to December 2023, we have implanted 379 prostheses, 79 of which were transcatheter (21.43%), with zero intraoperative mortality and a mortality rate of less than 1% during the first month of the intervention. To date, the incidence of established stroke in these patients is 0%.

4. Discussion

According to the latest Registry of Hemodynamics and Interventional Cardiology in Spain, in 2021 [9], a total of 5,270 transcatheter prostheses were implanted, with 94% of them being implanted via the right transfemoral route. In the same year, the results of the Registry of Interventions of the Spanish Society of Cardiovascular and Endovascular Surgery (RECC) [10] indicate that implants via the 'non-femoral' route in our country fell to 654, with 84% via the transaxillary or transcatheter route, and 16% via the transapical or transaortic route. As can be seen, there is a great difference between the number of transcatheter prostheses implanted via the transfemoral or non-femoral route, a consequence of the unequal situation and the lack of consensus in the Heart Team for decision-making.

5. Conclusions

The followings are the main conclusions we have drawn in our center regarding the use of the transcarotid approach:

We have adopted the transcarotid approach as an equally valid alternative to transaxillary access (and sometimes preferential to it and with better results), whose use will depend on the individual characteristics of each patient, and on the separate evaluation of each of his arteries, for which the preoperative study is essential. There is no single route that can be standardized for all patients and, therefore, we should not adapt the patient to the access route, but rather the access route to each patient [8].

As with the transaxillary approach, the transcarotid approach should be surgical, since the access represents minimal invasion. In this case, only the skin and subcutaneous cellular tissue are dissected, without muscle cutting, always performed under direct vision for vessel control. In addition, the possible curves that could be seen in the CT scan are absolutely correctable, since it is an unsupported artery and simply by traction of the distal vessel loop the tortuosities are corrected.

We believe that the carotid artery is an alternative vessel to the femoral artery and, in some cases, preferable for patients with good femoral access but with tortuosity and elongation of the iliac and thoracic aorta, which complicate the procedure and make optimal implantation of the prosthesis less predictable, due to difficulties in navigation and control of the implant at a great distance. Carotid access allows direct transmission of movement over the delivery system and very precise control of its position. Only a double-blind comparative study would remove these doubts.

We believe that the involvement of the cardiovascular surgeon in the decision-making process and TAVI implantation is of vital importance, and that it is necessary to perform the implantation in the operating room in order to have this "rescue option". The trend is to implant transcatheter valves in increasingly younger patients with lower surgical risk, given the results of recent studies such as the Evolut Low Risk [11] or PARTNER 3 studies.

Conflicts of Interest

The author declares no conflicts of interest regarding the publication of this paper.

References

- [1] Cribier A. Percutaneous transcatheter implantation of an aortic valve prosthesis for calcific aortic stenosis: first human case description. *Circulation*. 2002;106:3006-8, <http://dx.doi.org/10.1161/01.cir.0000047200.36165.b8>.
- [2] Patel JS, Krishnaswamy A, Svensson LG, Murat Tuzcu E, Mick S, Kapadia SR. Access options for transcatheter aortic valve replacement in patients with unfavorable aortoiliac anatomy. *Curr Cardiol Rep*. 2016;18:110, <http://dx.doi.org/10.1007/s11886-016-0788-8>. PMID: 27650782. Disponible en: <https://europepmc.org/article/med/27650782>
- [3] Walther T, Falk V, Borger MA, Dewey T, Wimmer-Greinecker G, Schuler G, et al. Minimally invasive transapical beating heart aortic valve implantation - proof of concept. *Eur J Cardiothorac Surg*. 2007;31:9-15, <http://dx.doi.org/10.1016/j.ejcts.2006.10.034>.
- [4] Faroux L, Junquera L, Mohammadi S, del Val D, Muntané-Carol G, Alperi A, et al. Femoral versus nonfemoral subclavian/carotid arterial access route for transcatheter aortic valve replacement: a systematic review and meta-analysis. *J Am Heart Assoc*. 2020;9:e017460, <http://dx.doi.org/10.1161/JAHA.120.017460>.
- [5] Folliguet T, Laurent N, Bertram M, Zannis K, Elfarra M, Vanhuysse F, et al. Transcarotid transcatheter aortic valve implantation: multicentre experience in France. *Eur J Cardiothorac Surg*. 2018;53:157-61, <http://dx.doi.org/10.1093/ejcts/ezx264>.

[6] Modine T, Lemesle G, Azzaoui R, Sudre A. Aortic valve implantation with the CoreValve ReValving System via left carotid artery access: first case report. *J Thorac Cardiovasc Surg.* 2010;140:928-9, <http://dx.doi.org/10.1016/j.jtcvs.2010.03.001>. PMID: 20381818. Disponible en: [https://www.jtcvs.org/article/S0022-5223\(10\)00231-X/fulltext](https://www.jtcvs.org/article/S0022-5223(10)00231-X/fulltext)

[7] Mack MJ, Leon MB, Thourani VH, Makkar R, Kodali SK, Russo M, et al., PARTNER 3 Investigators. Transcatheter aortic-valve replacement with a balloonexpandable valve in low-risk patients. *N Engl J Med.* 2019;380:1695-705, <http://dx.doi.org/10.1056/NEJMoa1814052>.

[8] Macías Rubio D, Vignau Cano JM, Gómez Vidal MA, Daroca Martínez T. TAVI transaxilar: la técnica paso a paso. *Cir Cardiovasc.* 2018;25:186-90, <http://dx.doi.org/10.1016/j.circv.2018.06.001>.

[9] Registro Espanol de Hemodinámica y Cardiología Intervencionista. XXXI informe oficial de la Asociación de Cardiología Intervencionista de la Sociedad Espanola de Cardiología (1990-2021). Disponible en: <https://doi.org/10.1016/j.recesp.2022.08.008>.

[10] Cirugía cardiovascular en España en el año 2021. Registro de intervenciones de la Sociedad Espanola de Cirugía Cardiovascular y Endovascular (RECC). Disponible en: [10.1016/j.circv.2023.04.003](https://doi.org/10.1016/j.circv.2023.04.003).

[11] Forrest J, Deeb G, Yakubov S, Gada H, Mumtaz MA, Ramlawi B, et al. 3-year outcomes after transcatheter or surgical aortic valve replacement in low-risk patients with aortic stenosis. *J Am Coll Cardiol.* 2023;81:1663-74, <http://dx.doi.org/10.1016/j.jacc.2023.02.017>.