

Pelvic Actinomycosis, Importance of a Suspected Diagnosis and Clinical Follow-up: A Case Report

Antonia Fontana Ostornol¹, Josefina Calvo Cruzat², Pablo Sandoval González^{3,4*}

1. Medicine, Universidad Finis Terrae, Santiago, Chile.

2. Medicine, Universidad Finis Terrae, Santiago, Chile.

3. Internal Medicine, Hospital Clínico UC Christus, Santiago, Chile.

4. Professor, School of Medicine, Universidad Finis Terrae, Santiago, Chile.

*Corresponding author. Email address: psandovalg@uft.edu

Abstract: Actinomycosis is a chronic granulomatous bacterial infection caused by the actinomyces species which frequently manifests as cervicofacial, thoracoabdominal or pelvic infections, the latter being the least frequent. There is a strong association between long term intrauterine device (IUD) use and the development of this infection. It is characterized by the formation of slow-growing abscesses that can reach large dimensions, generating an insidious and non-specific clinical presentation. Due to the above, the diagnosis is commonly late with a direct impact on the associated complications. Antibiotic treatment is usually prolonged and surgical interventions are sometimes required. We present the case of an IUD using patient who, after several months of symptoms, was hospitalized with the diagnosis of pelvic actinomycosis. The patient evolves favorably with abbreviated antibiotic treatments and outpatient clinical follow-up.

Key words: actinomycosis; pelvic inflammatory disease; intrauterine device; case reports

1. Introduction

Actinomycosis is a chronic granulomatous bacterial infection caused by actinomyces; Gram-positive, anaerobic, non-sporulating bacilli. This microorganism normally colonizes the oropharynx, gastrointestinal tract and vaginal canal. Therefore, actinomycosis usually manifests more frequently in the cervico-facial (60%), thoraco-abdominal (35%) and pelvic regions [1]. There are at least 30 species affecting humans, with actinomyces israelii being the most frequent [2].

The evolution of this infection is characterized by the formation of slow-growing granulomatous suppurative abscesses that can reach large dimensions. Diagnosis is usually delayed due to the nonspecific nature of the symptoms, and can be confused with other entities such as tuberculosis and pelvic neoplasms [2].

Management depends on the severity of the infection and associated complications, but usually requires prolonged and high-dose antibiotic treatment to eradicate the infection and in some cases surgical intervention is necessary.

We present the case of a 69-year-old female patient, long-time intrauterine device (IUD) carrier, who was hospitalized after months of non-specific symptoms under suspicion of abdominal neoplasia. The imaging study identified a large uterine mass with adnexal extension compatible with pelvic actinomycosis. In addition to the relevance of the differential

diagnosis of this case, the close clinical and imaging follow-up allowed a more limited and effective treatment.

This work aims to highlight the clinical presentation of pelvic actinomycosis, emphasizing the importance of clinical suspicion due to the nonspecific and larval nature of its symptoms. In addition, a more abbreviated treatment is proposed with respect to that indicated in the literature, based on medical follow-up.

2. Clinical Case

A 69-year-old woman with a history of hypertension, asthma, hypothyroidism and a pulmonary nodule. After several medical consultations, she was referred to endocrinology for 3 months of evolution characterized by asthenia, anorexia, intermittent abdominal discomfort and weight loss of approximately 10 kilos. Laboratory tests showed moderate normocytic anemia; Hb 9.6 g/dL [normal value: 12-16 g/dL], leukocytosis of 20,900 cells/ μ l [normal value: 4,500-11,000 cells/ μ l] with predominance of neutrophils (80%), thrombocytosis; 444,000 cells/ μ l [normal value: 140,000-400,000 cells/ μ l] and erythrocyte sedimentation rate (ESR) of 113 mm/h [normal value 1-29 mm/h in women >50 years].

She was referred to the emergency room with suspicion of abdominal neoplasia, and was admitted in good condition, with normal vital signs. Physical examination revealed pale mucous membranes, aortic systolic murmur and mild pain on palpation in the left flank.

The study was complemented with a CT scan of the abdomen and pelvis, which showed a large increase in uterine volume with left adnexal extension with cystic areas of abscessation, findings that concluded as compatible with pelvic actinomycosis, with evidence of an IUD (Figure 1).

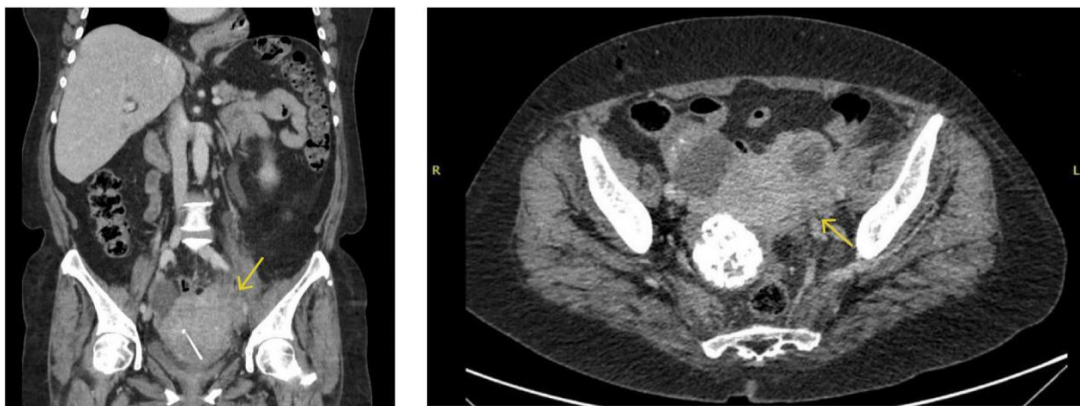


Figure 1. Computed tomography of the abdomen and pelvis. Coronal section (a) and axial section (b). Massive enlargement of the uterus with extension to the left adnexa with multiple cystic images with thickened walls, some suggestive of abscessation, with increased density of adipose tissue with an infectious inflammatory aspect. Inside the mass there is an IUD.

The patient is evaluated by gynecology for removal of the IUD and cytological study by Papanicolaou (PAP) which confirms the presence of actinomyces. Antibiotic therapy was started with high dose sodium penicillin with favorable clinical evolution and decrease of inflammatory parameters, dismissing the need for surgery. After a week of hospitalization, she was discharged to continue with ceftriaxone in home hospitalization. After 15 days, she was evaluated by internal medicine showing significant symptomatic improvement associated with increased hemoglobin and it was decided to change to oral amoxicillin 1 gram every 8 hours with monthly controls.

After 3 months of treatment, the patient was asymptomatic, with normalization of laboratory parameters; hemoglobin at 12.4 g/dL without leukocytosis or thrombocytosis, C-reactive protein <1.0 mg/dL [normal value <0.5 mg/dL] and HSV 2.0 mm/h, so antibiotic treatment was discontinued and an abdominal MRI was requested, which reported resolution of the pelvic inflammatory process. Finally, a last check-up was performed 3 months later and the patient remained asymptomatic, with no suspicion of recurrence and with weight recovery.

3. Discussion

Actinomycosis is a bacterial infection caused by microorganisms belonging to the genus actinomyces. It usually has a slow and painless progression. Since this bacterium is a resident of the oropharyngeal flora, gastrointestinal and genitourinary tract, mucosal transgression is necessary for infection and disease to occur [3].

Actinomyces infection falls into the group of "great imitators" since its clinical manifestations are broad and nonspecific, which often makes diagnosis difficult. It usually occurs after perforated appendicitis, intestinal perforations, complicated diverticulitis, associated with foreign bodies (for example, IUD use) or secondary to trauma [3]. Histologically, it is characterized by the formation of granulomas, abscesses and masses with abundant fibrous tissue that can extend to adjacent organs and give rise to fistulous tracts.

Pelvic actinomycosis is a rare disease, the prevalence of which is unknown given its low frequency [4]. However, in recent years, the incidence of female pelvic actinomycosis has been increasing, which is directly related to the increase in IUD insertion [5]. Several studies have shown that nearly 80% of women with endometritis, salpingo-oophoritis and abscesses due to actinomycotic infection are IUD users of more than 4 years of age [6].

Trauma and erosion of the endometrial endothelium caused by IUDs and the anaerobic environment in the uterine cavity are two conditions that facilitate invasion by bacteria such as actinomyces [2]. This explains why women with IUDs are up to four times more likely to develop a pelvic inflammatory process, especially after 2 years of IUD use [7].

The most common symptoms of pelvic actinomycosis are lower abdominal pain, weight loss and abnormal vaginal discharge, which is not always present as it was in this case. In up to 60% of cases, patients report intermittent fever. The latency time from the onset of symptoms to diagnosis is usually about 2 months [4].

The most frequent laboratory findings are leukocytosis with neutrophilia, normochromic normocytic anemia, elevated HSV and CRP as well as the tumor marker CA-125 [8].

With respect to imaging studies, these do not allow establishing a categorical diagnosis, however, they are usually very useful, in addition to providing information on the location, extension and evolution of the pathology. Magnetic resonance imaging would allow a better definition of the characteristics of the lesion. Generally, cystic or solid-cystic masses are observed, as well as perilesional fatty tissue of heterogeneous appearance, associated in some cases with lymphadenopathies [9].

Definitive diagnosis is made by culture; however, this is not routine practice since only 30-50% of cases are positive [1]. Gram-positive microorganisms with the presence of azurophilic granules (actinomyces conglomerates) are most commonly found in pathology specimens. When feasible, endometrial biopsy is also useful, allowing the identification of characteristic granulomas. Another diagnostic method may be by cytology, although only half of women have a positive PAP for actinomyces [4].

In-hospital treatment is usually with penicillin (10 to 20 million units per day divided into 4 or 6 doses). Alternatively, intravenous ceftriaxone can be used. Although this bacterium is very sensitive to β -lactams, the duration of antibiotic regimens is extensive, generally 6 to 12 months. Surgical interventions are avoided considering the great local inflammatory reaction with formation of large masses that makes it difficult to establish surgical planes, with the consequent risk of generating fistulas. However, in some cases of greater severity, they are necessary [10].

In relation to the case presented, we would like to highlight the significant delay in the diagnosis due to the lack of specificity of the symptoms and laboratory findings, added to the low clinical suspicion. However, despite the extended time of disease and the large abdominal mass with signs of abscessation, the favorable evolution with medical management alone dismissed the need for surgical drainage.

In addition, the close clinical follow-up allowed a more limited antibiotic treatment compared to what is reported in the literature, with the benefit of reducing antibiotic exposure and, along with it, the adverse effects and costs.

It is important to point out that the recurrence of this infection is high when optimal treatment is not carried out and in this case the decision to complete only 3 months of antibiotic therapy was possible because the patient met certain characteristics: favorable clinical evolution, good oral tolerance, adequate understanding of medical indications, continuity of controls and good support network at home.

4. Conclusion

Pelvic actinomycosis is an infrequent clinical entity, whose clinical manifestations are broad and nonspecific, generating a delay in consultation and diagnosis. It is essential to maintain a high clinical suspicion including this entity in the differential diagnosis of chronic abdominal pain or constitutional symptoms such as anorexia, fatigue and weight loss. Among the differential diagnoses, tubo-ovarian abscesses, Crohn's disease, diverticulitis, endometriosis, neoplasms and tuberculosis should be considered. Although treatment depends on the clinical presentation and evolution, it is usually prolonged; however, it is possible to propose more limited schemes in selected patients and as long as it is accompanied by an adequate follow-up.

Ethical Considerations

This clinical case report was conducted in accordance with the Code of Ethics of the Declaration of Helsinki, safeguarding the privacy and confidentiality of patient data and with the patient's informed consent.

Conflicts of Interest

The author declares no conflicts of interest regarding the publication of this paper.

References

- [1] Wong VK, Turmezei TD, Weston VC. Actinomycosis. *BMJ*. 2011;343:d6099. doi: 10.1136/bmj.d6099
- [2] Valour F, Sénéchal A, Dupieux C, Karsenty J, Lustig S, Breton P, et al. Actinomycosis: etiology, clinical features, diagnosis, treatment, and management. *Infect Drug Resist*. 2014;7:183-197. doi: 10.2147/IDR.S39601
- [3] Sánchez Guzmán AV, Mora Calderón A. Actinomicosis pélvica: relación con dispositivos intrauterinos. *Rev Clin Esc Med UCR-HSJD*. 2015;5(5):11-15. doi: 10.15517/rc_ucr-hsjd.v5i5.21699
- [4] Daniels P, Correa E, Goity C. Actinomicosis pelviana: caso clínico. *Rev Chil Obstet Ginecol*. 2013;78(1):48-50. doi: 10.4067/S0717-75262013000100008
- [5] Han Y, Cao Y, Zhang Y, Niu L, Wang S, Sang C. A case report of pelvic actinomycosis and a literature review. *Am J Case Rep*. 2020;21:e922601. doi: 10.12659/AJCR.922601
- [6] Bustos-Moya G, Josa-Montero D, Perea-Ronco J, Gualtero-Trujillo S. Enfermedad pélvica inflamatoria por *Actinomyces* sp. en paciente condispositivo intrauterino: reporte de un caso. *Infect*. 2016;20(1):33-36. doi: 10.1016/j.infect.2015.07.005
- [7] Suárez M, Estrada E, Espada E. Prevalencia de actinomicosis uterina y anexos en el período 1996-2002, Provincia de Ciego de Ávila, Cuba. *Bol Micol*. 2004;19:19-21. doi: 10.22370/bolmicol.2004.19.0.290
- [8] García-García A, Ramírez-Durán N, Sandoval-Trujillo H, Romero Figueroa MDS. Pelvic actinomycosis. *Can J Infect Dis Med Microbiol*. 2017:9428650. doi: 10.1155/2017/9428650
- [9] Lee IJ, Ha HK, Park CM, Kim JK, Kim JH, Kim TK, et al. Abdominopelvic actinomycosis involving the gastrointestinal tract: CT features. *Radiology*. 2001;220(1):76-80. doi: 10.1148/radiology.220.1.r01j11376
- [10] Hamid D, Baldauf JJ, Cuenin C, Ritter J. Treatment strategy for pelvic actinomycosis: case report and review of the literature. *Eur J Obstet Gynecol Reprod Biol*. 2000;89(2):197-200. doi: 10.1016/s0301-2115(99)00173-6